Repairing the Corneal Nerve Bed using Collagen Mimetic Peptides

Research to Prevent Blindness

VANDERBILT UNIVERSITY MEDICAL CENTER

Lauren K. Wareham[1], Joseph M. Holden[1], Olivia L. Bossardet[1], Robert O. Baratta[2], Brian J. Del Buono[2], Eric Schlumpf[2], George W. Ousler[3] and David J. Calkins[1]

[1]Vanderbilt Eye Institute, Vanderbilt University Medical Center, Nashville, Tennessee, USA, [2]Stuart Therapeutics, Inc., Stuart, Florida, USA; [3]Ora Inc, Andover, Massachusetts, USA

Introduction

- The corneal nerve bed is critical in maintaining the homeostatic function of the ocular surface. Corneal nerve bed damage is endemic to dry eye disease (DED), the most prevalent progressive ocular surface disease, afflicting millions of people worldwide.
- The cornea contains a high concentration of collagen, which is susceptible to damage in conditions such as DED and may represent a novel therapeutic target[1].
- Collagen mimetic peptides (CMPs) are short peptides that bind to fragmented helical collagen[1].
- We tested whether topical application of a CMP (Pro-Pro-Gly)$_7$ was efficacious in repairing the corneal nerve bed in a mouse model of DED.

Methods

- Male/female wild type C57/B6 mice aged 12 weeks
- **Desiccation model (DEM):** 1% topical atropine 4x daily and fan desiccation for 12 hours/day
- Topical CMP (Pro-Pro-Gly)$_7$) 200μM applied 1x daily

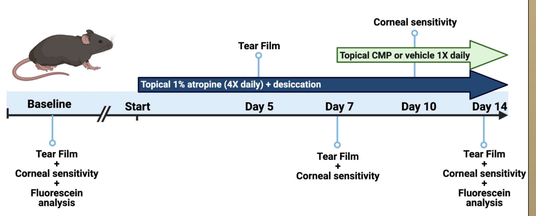

1) CMP improves tear film and corneal sensitivity

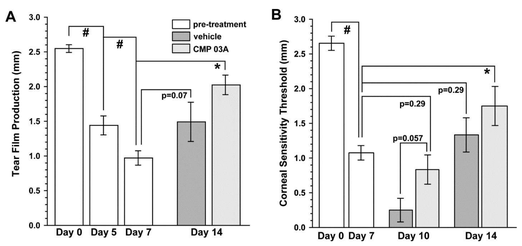

Figure 1. (A) Tear film production was significantly reduced after 5 and 7 days (#, p<0.001) compared to baseline (day 0). Tear film production did not improve in vehicle-treated mice (p = 0.07), but did with CMP (*, p <0.001). **(B)** Corneal sensitivity was significantly reduced after 7 days (#, p<0.001). After 3 days of vehicle treatment, sensitivity was further reduced (p = 0.057), but not with CMP (p = 0.29). By day 14, CMP improved sensitivity (*, p =0.01), while vehicle did not (p = 0.29).

2) CMP prevents sub-basal + epithelial corneal nerve bed degeneration

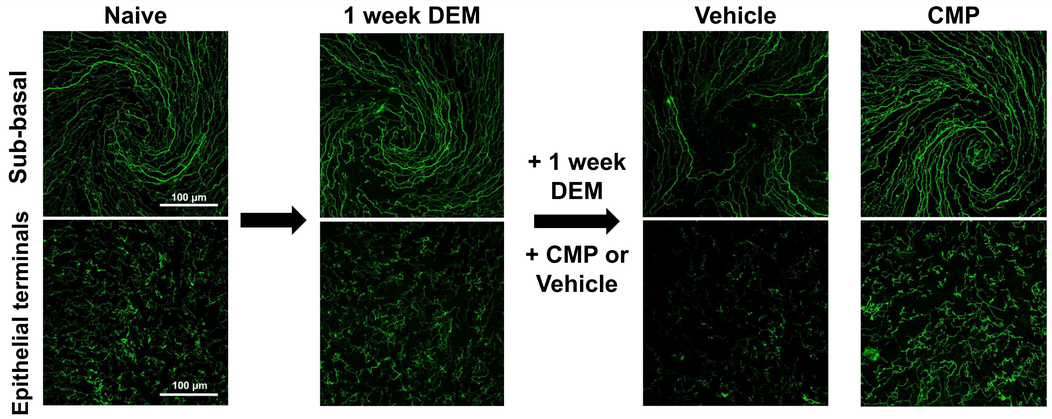

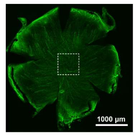

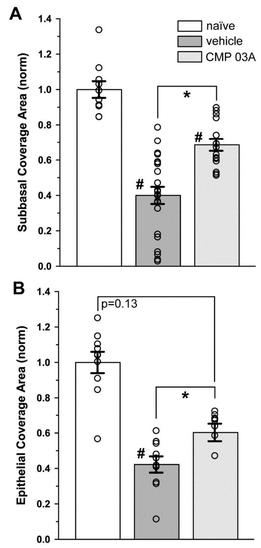

Figure 2. Representative confocal images of βIII-tubulin-stained nerve fibers in the central cornea with images of the central sub-basal plexus and epithelial terminals. Left image shows example whole cornea and dashed box = central swirl location. Naïve animals have an intact and robust sub-basal plexus and nerve terminal coverage. The desiccation model (DEM) had similar nerve density after 1 week. At 2 weeks, DEM + vehicle had reduced nerve coverage. CMP-treated prevented a loss of nerve coverage at the **(A)** sub-basal and **(B)** terminal epithelial plexus. Scale bars as indicated. (#,* p < 0.001).

3) CMP prevents nerve fragmentation



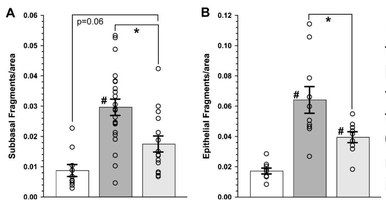

Figure 3. At day 14 fragmentation in the sub-basal plexus and epithelial terminals was increased 3-fold with vehicle (p < 0.001), but significantly reduced with CMP by 40% in both zones (p ≤ 0.02).

4) CMP preserves the epithelium

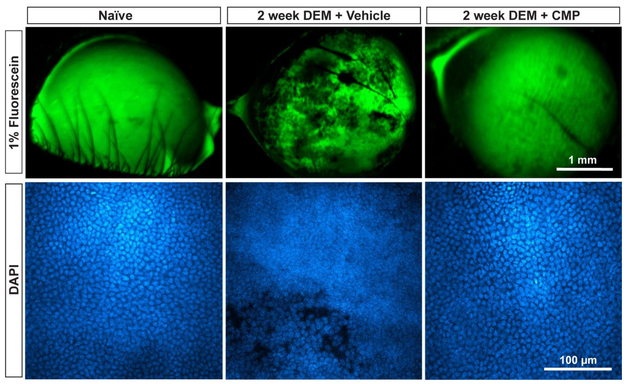

Figure 4. Top row = representative images of the corneal epithelial surface in naïve, vehicle-, and CMP-treated mice visualized *in vivo* by fluorescein staining after 2 weeks of the DEM. CMP prevented corneal epithelial pitting observed in the vehicle group. **Bottom row =** representative DAPI-stained confocal images of the epithelial layer in naïve, vehicle- and CMP -treated mice. Vehicle treatment caused epithelial disruption that is absent in the CMP 03A-treated cohort and comparable to naïve animals. Scale bars as indicated.

5) Phase II CMP Clinical trial

- Participants were of either sex and of any race who were at least 18 years of age with a subject-reported history of DED for at least 6 months.
- ST100 = CMP (50 μg/ml) topical for 29 days.
- **Schirmer's Test Responder Rate** = a statistically significant difference between the proportion of subjects who received treatment and achieved a ≥ 10 mm Schirmer's test change from baseline (CFB) as defined by the FDA for treatment of DED.

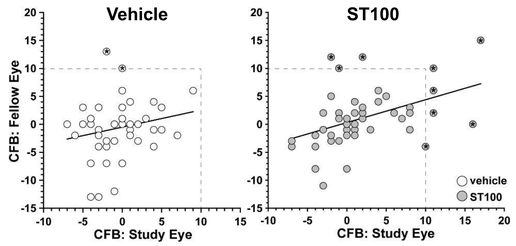

Figure 5. ST100 improves Schirmers tear film score. CFB = change from baseline day 29 vs. day 1. * marks "responders" = a gain of 10 mm in Schirmers. ST-100 achieved the Schirmer's Test Responder Rate endpoint, compared to the vehicle group (p = 0.0266; Fisher's Exact Test), with a difference of proportions of 0.122 (Exact two-sided 95% CI = -0.075, 0.315).

Conclusions

- CMP treatment in the 2-week DEM prevented corneal nerve bed degeneration compared to vehicle.
- CMP preserved epithelial integrity compared to vehicle.
- CMP only partially restored tear film volume and corneal sensitivity, suggesting nerve bed repair was independent of tear film volume.
- CMPs show promise in the treatment of DED after phase II clinical trials and may present a novel therapeutic avenue for the disease.

References

[1] Baratta *et al*, Survey of Ophthal. 2022, 67(1), 60-67.

Acknowledgements and Funding Sources

- The study received funding from Stuart Therapeutics, Inc. and from unrestricted funds to Dr. David J. Calkins.
- Confocal microscopy was supported in part by the Vanderbilt Vision Research Center Scholarship and the Vanderbilt University School of Medicine "Cell and the Imaging Shared Resource (CISR)" which is supported by NIH grants CA68485, DK20593, DK58404, DK59637 and EY08126.